

ISSN 1007-9327
CN 14-1219/R



WJG

World Journal of Gastroenterology®

Indexed/Abstracted by
Science Citation Index®-Expanded, Research Alert®,
Current Contents®/Clinical Medicine, Journal Citation Reports®,
Index Medicus, MEDLINE, Chemical Abstracts,
EMBASE/Excerpta Medica and Abstract Journal.
The Journal's 2002 Impact Factor is 2.532, According to JCR®

Volume 9

Number 10

October

2003

Massive gastrointestinal tuberclosis in a young patient without immunosuppression

Yasar Settbas, Murat Alper, Yusuf Akcan, Yesim Gurbuz, Sükrü Oksuz

Yasar Settbas, Resident, A.I.B.U. Duzce Medical Faculty, Department of Internal Medicine, Duzce, Turkey

Murat Alper, Assistant professor, A.I.B.U. Duzce Medical Faculty, Department of Pathology, Duzce, Turkey

Yusuf Akcan, Assistant professor, A.I.B.U. Duzce Medical Faculty, Department of Internal Medicine, Duzce, Turkey

Yesim Gurbuz, Assistant professor, Kocaeli University Medical Faculty, Department of Pathology, Duzce, Turkey

Sükrü Oksuz, Resident, A.I.B.U. Duzce Medical Faculty, Department of Microbiology

Correspondence to: Yasar Settbas, M.D., Abant İzzet Baysal University Duzce Medical Faculty Department of Internal Medicine, 14450, Konuralp, Duzce, Turkey. ysertbas@hotmail.com
Telephone: +90-380-5414107 **Fax:** +90-380-5414105

Received: 2002-10-17 **Accepted:** 2002-11-09

Abstract

Although the lung is the major site for *Mycobacterium tuberculosis* infection, gastrointestinal involvement can be present as part of multiorgan disease process or, less commonly, can be seen as primary gastrointestinal tuberculosis. In the cases where the culture is negative, it can be difficult to differentiate tuberculosis from Crohn's disease based on both the clinical and histological features. When side effects of classic antimycobacteria are encountered, we can initially add ciprofloxacin to the treatment of tuberculosis. We reported a case of 19-yr-old patient, who was treated as Crohn's disease and worsen. We began to tuberculosis treatment, and the patient improved clinically and histologically. The main point in this case is that widespread involvement of gastrointestinal tract can be brought about by non resistant strains of *Mycobacterium tuberculosis* even in immunocompetent patients.

Settbas Y, Alper M, Akcan Y, Gurbuz Y, Oksuz S. Massive gastrointestinal tuberclosis in a young patient without immunosuppression. *World J Gastroenterol* 2003; 9(10):2382-2384
<http://www.wjgnet.com/1007-9327/9/2382.asp>

INTRODUCTION

Mycobacterium tuberculosis is the primary cause of tuberculosis, infects one third of world's population and causes the most deaths per year of any infectious agents. It is found primarily in developing countries, where poor sanitation contributes to its spread. Although pulmonary manifestations predominate in most tuberculosis cases, gastrointestinal involvement may be present as a part of multiorgan disease process or, less commonly as primary gastrointestinal tuberculosis. Gastrointestinal tuberculosis is usually caused by *Mycobacterium tuberculosis* but may also be caused by *Mycobacterium bovis*. Prior to AIDS epidemic, it was seen most commonly in immune competent persons with untreated advanced pulmonary disease^[1]. Today, it is most commonly observed in association with immunosuppression and, in one series, more than 40% of patients with gastrointestinal tuberculosis had AIDS^[2]. Other groups at highest risk include

those who abuse alcohol, injection drug users, those who take chronic steroids, elderly persons. Here, we described a case of gastrointestinal tuberculosis with diffuse involvement of esophagus, stomach, ileum and colon, who did not possess any known immunosuppressive state in his history (Diabetes mellitus, alcohol abuse, protein calor malabsorption, AIDS).

CASE REPORT

A 19 year old male patient presented to the outpatient department with complaints of dyspepsia and nausea for two years. Recently, vomiting after meals made the patient fear of eating. He first received anti ulcer medication with the diagnosis of peptic ulcer in another center. Since his complaints continued, endoscopic and colonoscopic examinations were performed and several biopsies were obtained. A diagnosis of Crohn's disease was made at the same center. Lansaprazol 30 mg, mesalazine (500 mg *p.o. t.i.d.*), hydrocortisone 10 mg/kg/day were begun. Despite the treatment regimen, no response to mesalazine and hydrocortisone was seen and since his complaints increased, he was admitted to our center with abdominal pain, anorexia, nausea, fatigue, weight loss (15 kg/6 month). There were no pathologic findings on his chest x-ray. Ultrasound examination of the abdomen revealed unremarkable findings, except some degree of cachexia and apathetic appearance. Laboratory data included hemoglobin 11.5 g/dL, erythrocyte sedimentation rate 10 mm/hr, alanin aminotransferase 30 U/L, aspartat aminotransferase 40 U/L, total protein 4.1 g/dL, albumin 2 g/dL, white blood cell count 6 600, platelet count 314 000, HBsAg (-), AntiHBsAg(-), Anti-HCVAg(-), HIV(-) and PPD levels 7 mm. Physical examination did not find any abnormal findings. He had no history of any disease which practically can cause diabetes mellitus, alcoholism and renal insufficiency, which are associated with immunodeficiency.

Endoscopy and colonoscopy were performed due to these complaints in our institution. Endoscopy revealed hyperemia with granulomatous lesions at the lower third of the esophagus. A granular appearance was seen along small curvature of the corpus. Antrum had extensive hyperemia. Additionally granulomas were seen at bulbar and the second part of duodenum. Subsequently biopsies were obtained from all described areas. A histopathological examination revealed existence of granuloma in the esophagus, stomach and small intestine with caseous necrosis in the stomach (Figures 1-3). Although ileal biopsy revealed edematous lamina propria with increase of inflammatory cells, there was a granulation at the ileal biopsy which was done 3 months before the treatment of Crohn's disease started at another center (Figure 4).

Under the light microscopy of these findings, gastrointestinal tuberculosis was concluded and treated with anti tuberculosis treatment of isoniazid 200 mg/day, rifampicin 450 mg/day, morfazinamid 1 g/day and ethambutol 500 mg/day. During the follow up of the first and second month, retrobulbar neuritis and peripheral neuritis were seen as the side effects of ethambutol and isoniazid respectively. At the second month of the treatment, morfazinamid was also stopped. Ciproxin 500 mg two times a day with the combination of rifampicin 450 mg/day was given. A significant improvement in clinical

situation of the patient was observed. He gained 25 kg during the therapy and got 60 kg. The patient received anti tuberculosis treatment for 12 months. Check up endoscopy at the end of treatment revealed normal findings with no granulation and caseous necrosis.



Figure 1 Granulomatous structures of esophagus (H & E×100).

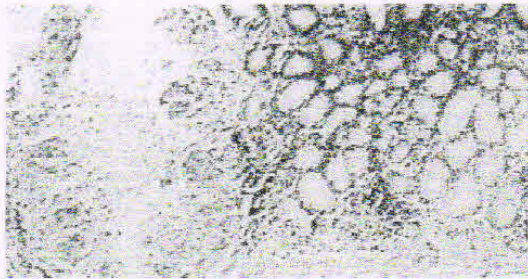


Figure 2 Granulomatous structures and caseous necrosis in the mucosa of stomach (H & E×100).

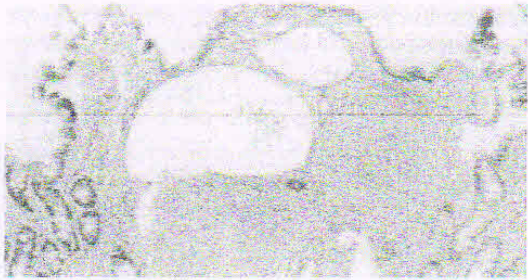


Figure 3 Granulomatous structures in the mucosa of small intestine (H & E×100).

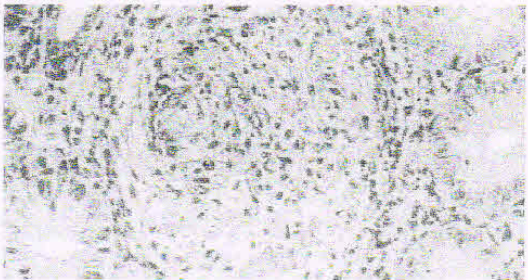


Figure 4 Granulomatous structures between glands of colon mucosa (H & E×310).

DISCUSSION

The diagnosis of gastrointestinal tuberculosis is always difficult. We must keep in mind the possibility of patients with abdominal pain, even without concomitant lung involvement^[2,3]. Tuberculosis may affect any part of gastrointestinal tract, but it most commonly involves the terminal ileum and ileocaecal region, as Crohn's disease did^[4]. However it is rare to see the involvement of all parts of the gastrointestinal tract. Therefore, our case is interesting as almost the whole gastrointestinal tract has been affected.

The symptoms of gastrointestinal tuberculosis are nonspecific, and in the absence of pulmonary tuberculosis the diagnosis may be difficult. The most common symptom associated with gastrointestinal tuberculosis is abdominal pain. Other symptoms included diarrhea, fever, anorexia, weight loss, constipation, and hemorrhage^[5].

A presumptive diagnosis can be made in the presence of known active pulmonary tuberculosis and based on the clinical and radiological findings in the bowel. Definitive diagnosis is essentially made by histology, with Ziehl-Neelsen staining for acid fast bacilli and culture. Colonoscopy and endoscopy of gastrointestinal system are the most useful nonoperative diagnostic tools. A combination of histology and culture can establish the diagnosis up to 80 % of the patients. Although more expensive PCR of biopsy specimens may facilitate diagnosis since it has higher sensitivity and specificity than routine culture, and results could be obtained in 48 hours instead of weeks^[6]. The detection of anti-cord antibodies has recently been shown to facilitate the diagnosis of intestinal tuberculosis from Crohn's disease^[7]. However, the cases, which have negative results of culture and PCR can be seen and the diagnosis is achieved through histological assessment and response to antituberculosis treatment. Sometimes we could see the cases that had culture and PCR negative results were diagnosed histologically and recovered by tuberculosis treatment^[8]. In our case, we established the diagnosis of tuberculosis by the presence of caseation and granulomatous lesions suggestive of tuberculosis, and essentially by the occurrence of dramatic clinical improvement.

The lesions of gastrointestinal tuberculosis have clinically been divided into an acute ulcerative stage and chronic hypertrophic stage of the disease that is characterized by granulomas and extensive fibrosis. Ulcers are typically irregular with a necrotic base, which may extend to perforation. *Fistulae* and anorectal lesions may occur. These features are nonspecific, and can also be seen in Crohn's disease. In contrast, distinguishing histological features of granulomas in intestinal tuberculosis from Crohn's disease have been described. Caseation, if present, strongly suggests tuberculosis. However central acute necrosis of granulomas may also be seen occasionally in Crohn's disease.

Tuberculosis should always be considered in the differential diagnosis of patients with obscure abdominal symptoms. Other entities, which are commonly misdiagnosed are Crohn's disease, lymphoma, carcinoma, diverticular diseases, appendicitis and other infections of gastrointestinal tract. Ulcers were more typically linear, and granulomas, when they were found had no caseation necrosis or organisms^[9,10].

The prognosis of gastrointestinal tuberculosis depends primarily on the immune status of the appropriate therapy in a timely manner. In untreated HIV-infected patients, the disease progresses rapidly and is almost always fatal. If there is suspicious tuberculosis as histologically, treatment should begin without waiting the result of the culture. The regimen of choice in most of the cases is isoniazid 3 to 5 mg/kg, rifampin 10 mg/kg, pyrazinamid 20-25 mg/kg and ethambutol 15 mg/kg all given once daily. In resistant cases ciprofloxacin can be used. However in our case because of the side effects of

situation of the patient was observed. He gained 25 kg during the therapy and got 60 kg. The patient received anti tuberculosis treatment for 12 months. Check up endoscopy at the end of treatment revealed normal findings with no granulation and caseous necrosis.



Figure 1 Granulomatous structures of esophagus (H & E×100).

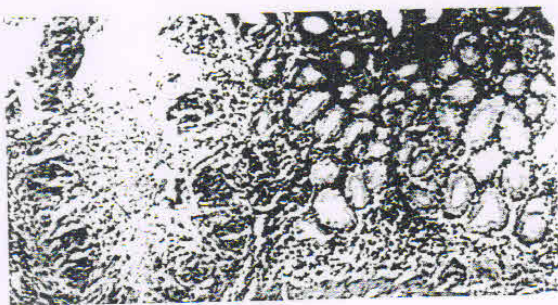


Figure 2 Granulomatous structures and caseous necrosis in the mucosa of stomach (H & E×100).

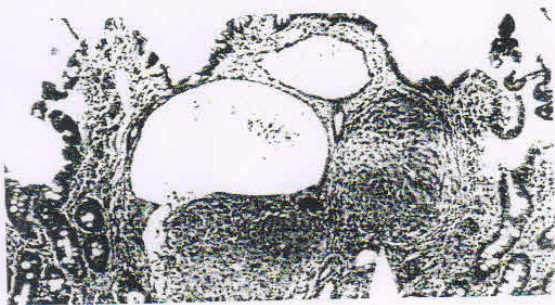

Figure 3 Granulomatous structures in the mucosa of small intestine (H & E×100).

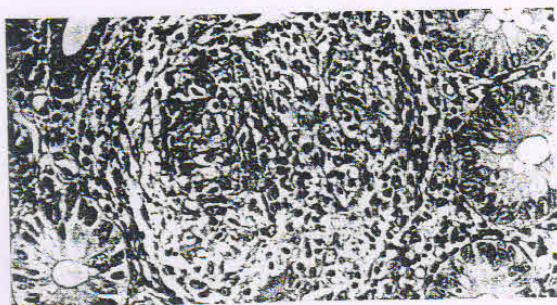


Figure 4 Granulomatous structures between glands of colon mucosa (H & E×310).

DISCUSSION

The diagnosis of gastrointestinal tuberculosis is always difficult. We must keep in mind the possibility of patients with abdominal pain, even without concomitant lung involvement^{2,3}. Tuberculosis may affect any part of gastrointestinal tract, but it most commonly involves the terminal ileum and ileocaecal region, as Crohn's disease did⁴. However it is rare to see the involvement of all parts of the gastrointestinal tract. Therefore, our case is interesting as almost the whole gastrointestinal tract has been affected.

The symptoms of gastrointestinal tuberculosis are nonspecific, and in the absence of pulmonary tuberculosis the diagnosis may be difficult. The most common symptom associated with gastrointestinal tuberculosis is abdominal pain. Other symptoms included diarrhea, fever, anorexia, weight loss, constipation, and hemorrhage⁵.

A presumptive diagnosis can be made in the presence of known active pulmonary tuberculosis and based on the clinical and radiological findings in the bowel. Definitive diagnosis is essentially made by histology, with Ziehl-Neelsen staining for acid fast bacilli and culture. Colonoscopy and endoscopy of gastrointestinal system are the most useful nonoperative diagnostic tools. A combination of histology and culture can establish the diagnosis up to 80 % of the patients. Although more expensive PCR of biopsy specimens may facilitate diagnosis since it has higher sensitivity and specificity than routine culture, and results could be obtained in 48 hours instead of weeks⁶. The detection of anti-cord antibodies has recently been shown to facilitate the diagnosis of intestinal tuberculosis from Crohn's disease⁷. However, the cases, which have negative results of culture and PCR can be seen and the diagnosis is achieved through histological assessment and response to antituberculosis treatment. Sometimes we could see the cases that had culture and PCR negative results were diagnosed histologically and recovered by tuberculosis treatment⁸. In our case, we established the diagnosis of tuberculosis by the presence of caseation and granulomatous lesions suggestive of tuberculosis, and essentially by the occurrence of dramatic clinical improvement.

The lesions of gastrointestinal tuberculosis have clinically been divided into an acute ulcerative stage and chronic hypertrophic stage of the disease that is characterized by granulomas and extensive fibrosis. Ulcers are typically irregular with a necrotic base, which may extend to perforation. *Fistulae* and anorectal lesions may occur. These features are nonspecific, and can also be seen in Crohn's disease. In contrast, distinguishing histological features of granulomas in intestinal tuberculosis from Crohn's disease have been described. Caseation, if present, strongly suggests tuberculosis. However central acute necrosis of granulomas may also be seen occasionally in Crohn's disease.

Tuberculosis should always be considered in the differential diagnosis of patients with obscure abdominal symptoms. Other entities, which are commonly misdiagnosed are Crohn's disease, lymphoma, carcinoma, diverticular diseases, appendicitis and other infections of gastrointestinal tract. Ulcers were more typically linear, and granulomas, when they were found had no caseation necrosis or organisms^{9,10}.

The prognosis of gastrointestinal tuberculosis depends primarily on the immune status of the appropriate therapy in a timely manner. In untreated HIV-infected patients, the disease progresses rapidly and is almost always fatal. If there is suspicious tuberculosis as histologically, treatment should begin without waiting the result of the culture. The regimen of choice in most of the cases is isoniazid 3 to 5 mg/kg, rifampin 10 mg/kg, pyrazinamid 20-25 mg/kg and ethambutol 15 mg/kg all given once daily. In resistant cases ciprofloxacin can be used. However in our case because of the side effects of

ethambutol and isoniazid, ciprofloxacin was given^[1]. After a while of treatment histologic and clinical response was seen. It could be thought that ciprofloxacin could also be used in the treatment of Crohn's disease^[12]. Since the disease was worsen with the use of steroids, it should be thought that the effect of ciprofloxacin was against the tuberculosis.

This case report illustrates that the diagnosis of colonic tuberculosis requires a high index of suspicion. In cases where there is any doubt about the the diagnosis of Crohn's disease, and even if the histology of colonic biopsies suggests Crohn's disease, corticosteroids should be withheld due to disastrous results such as dissemination of tuberculosis. On the other hand, if the information not available to differentiate Crohn's disease from tuberculosis, therapeutic trial of tuberculosis is justified because it whould not aggravate Crohn's disease. In the cases of side affects of the drugs in tuberculosis, ciprofloxacin can be preferred in the combination with anti-mycobacterials which have no side affects. Tuberculosis of gastrointestinal tract can mostly be seen in immune compromised individuals such as HIV (+) individuals, alcoholic and chronic steroids users, but can also be seen in immunocompatible peoples. Although it's mostly seen in the ileocecal region of gastrointestinal tract, it must be kept in mind that it can be widedspreadly disseminated as in our case.

REFERENCES

- Pettengell KE, Larsen C, Garb M, Mayet FG, Simjee AE, Piri D. Gastrointestinal tuberculosis in patients with pulmonary tuberculosis. *Q J Med* 1990; **74**: 303-308
- Shafer RW, Kim DS, Weiss JP, Quale JM. Extrapulmonary tuberculosis in patients with human immunodeficiency virus infection. *Medicine* 1991; **70**: 384-397
- Perez del Rio MJ, Fresno Forcelledo M, Diaz Iglesias JM, Veiga Gonzalez M, Alveraz Prida E, Ablanedo Ablanedo P, Herrero Zapatero A. Intestinal Tuberculosis, a difficult suspected diagnosis. *An Med Interna* 1999; **16**: 469-472
- Brizi MG, Celi G, Scaldazza AV, Barbaro B. Diagnostic imaging of abdominal tuberculosis: gastrointestinal tract, peritoneum, lymph nodes. *Rays* 1998; **23**: 115-125
- Bouma BJ, Tytgata KM, Shipper HC, Kager PA. Be aware of abdominal tuberculosis. *Neth J Med* 1997; **51**: 119-122
- Gan H, Ouyang Q, Bu H, Li S, Chen D, Li G, Yang X. Value of polymerase chain reaction assay in diagnosis of gastrointestinal tuberculosis and differentiation from Crohn's disease. *Chin Med J* 1995; **108**: 215-220
- Kashima K, Oka S, Tabata A. Detection of anti-cord factor antibodies in intestinal tuberculosis for its differential diagnosis from Crohn's disease and ulcerative colitis. *Dig Dis Sci* 1995; **40**: 2630-2640
- Artu P, Lavergne-Slove, Joly F, Bitoun A, Ramboud JC, Bouhrik Y. Isolated jejunal tuberculosis mimicking Crohn disease. Diagnosis by push video enteroscopy. *Gastroenterol Clin Biol Biol* 1999; **23**: 1086-1089
- Jakubowski A, Elwood RK, Enarson DA. Clinical features of abdominal tuberculosis. *J Infect Dis* 1988; **158**: 687-692
- Tabrisky J, Lindstran RR, Peters R, Lachman RS. Tuberculous enteritis, Review of a protean disease. *Am J Gastroenterol* 1975; **63**: 49-57
- Beming SE. The role of fluoroquinolones in tuberculosis today. *Drugs* 2001; **61**: 9-18
- Peppercorn MA. Is there a role for antibiotics as primary therapy in Crohn's ileitis? *J Clin Gastroenterol* 1993; **17**: 235-237

Edited by Xu XQ and Wang XL.